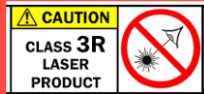

MANAGEMENT OF LASER POINTER INJURIES CAUSING SIGHT-THREATENING



RETINOPATHY



CAUTION

- chanelle28.smith@gmail.com
- ZOOM LINK
<https://us04web.zoom.us/j/71178033986?pwd=RWNuL2tvMmFoMINQR3dPQnB0NFU4Zz09>

INTRODUCTION:

- Powerful lasers have become increasingly available online with the FFA reporting an increase in laser attacks of 25% on Heathrow airport.
- Serious retinopathy can often lead to significant visual loss and the need for surgical intervention.

OBJECTIVE:

This literature review summarises the existing literature related to ocular damage secondary to high powered laser pointers. We also compare the extent of retinal damage associated with laser pointers of different colour and rated power and surgery needed to heal this retinopathy.

METHODS:

A comprehensive systemic review was performed. A review of 23 papers which document laser pointer exposure to 54 eyes from the last 5 years were identified. Key word search terms included “laser pointer maculopathy” and “macular laser injury”.

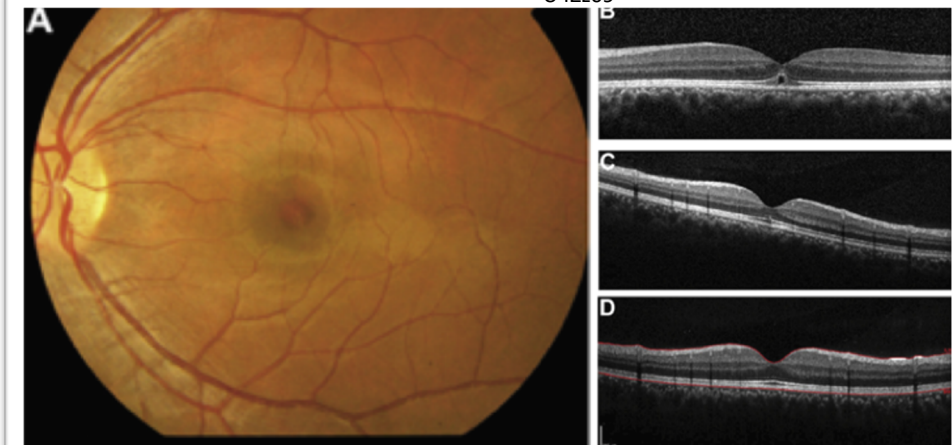

FIGURE 1 – A – Color fundus photograph of the left eye demonstrating pigmentary foveal changes following laser pointer exposure. B – Macular OCT scan demonstrating disruption of the IS/OS junction and RPE. C – Macular OCT scan 1 month post exposure with partial resolution. D- Macular OCT scan 2 months post exposure with complete resolution.

RESULTS:

- In 43% of cases, blue was the most commonly reported colour associated with laser pointer maculopathy.
- Many cases (41%) are unreported due to discrepancies between the labelled and actual power of lasers.
- Initial presenting visual acuity was 0.30 or worse in 91% of cases.
- 89% had an improved final visual acuity compared to their presenting visual acuity.
- 31% needed surgical intervention of which 30% of patients had a final visual acuity of 0.10 or less even with surgical intervention.

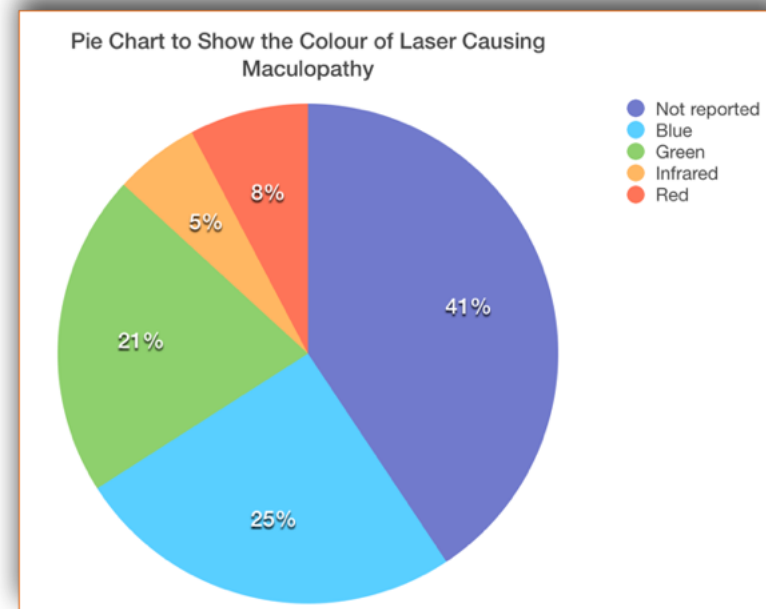


FIGURE 2 – A – A pie chart to show the color of laser causing maculopathy. While 41% is unreported, blue has the highest proportion (25%) of laser pointer maculopathy.

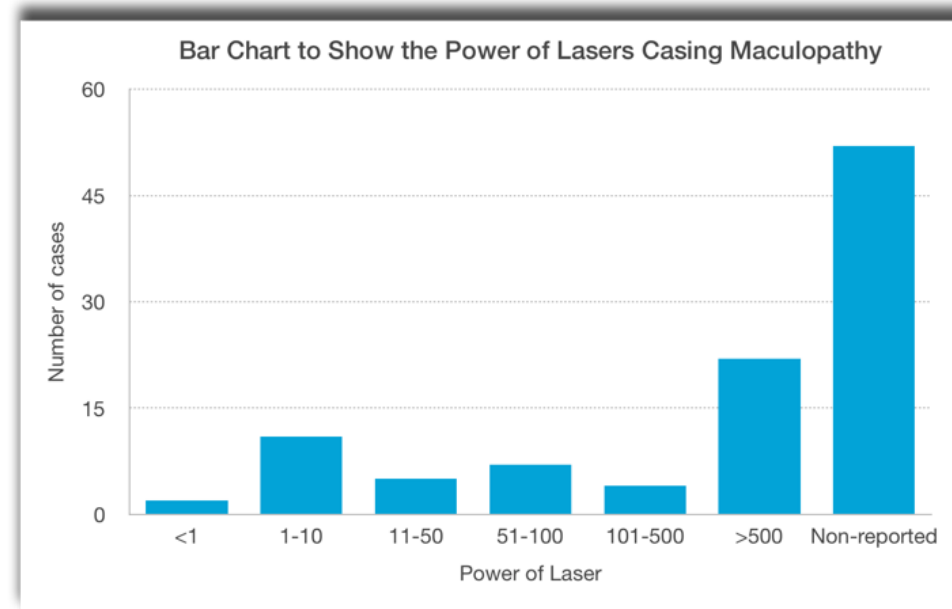


FIGURE 3 – A – A bar chart the show the power of lasers causing maculopathy. While most was unreported, the highest proportion were >500mW, far above the legal limit.

CONCLUSION: **DANGER**

Public awareness should be encouraged of illegal laser pointers. They can produce devastating visual sequelae and most cases require surgical and medical intervention. Further research is required to determine the most effective initial management for affected patients.